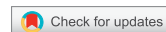

<https://doi.org/10.21516/2072-0076-2021-14-3-65-72>

# Central serous chorioretinopathy in uveitis patients after corticosteroid therapy: a report of 6 cases

Natalia Skvortsova<sup>1, 2</sup> ✉, Ioannis Papasavvas<sup>2</sup>, Carl P. Herbort<sup>2</sup> ✉

<sup>1</sup> Posterior Eye Segment Diagnostics and Surgery Center, Moscow, Russian Federation

<sup>2</sup> Inflammatory and Retinal Eye Diseases, Centre for Ophthalmic Specialised Care, Lausanne, Switzerland  
nat.skvortsova@gmail.com

**Purpose.** To report central serous chorioretinopathy (CSCR) in uveitis patients. **Material and methods.** A retrospective chart review of uveitis patients seen in a time frame of 20 years at the Centre for Ophthalmic Specialised Care, Lausanne, Switzerland. The ophthalmic and systemic features are presented. **Results.** Out of 1793 uveitis patients followed at the Centre for Ophthalmic Specialised Care, 6 patients (0.3%) developed CSCR following corticosteroid therapy due to uveitis. The mean age of patients was  $40 \pm 13.4$  years, disease incidence was not associated with gender. In all 6 patients' clinical disease was unilateral but subclinical signs were present in all fellow eyes. The mean duration of corticosteroid therapy before CSCR had occurred was  $4.95 \pm 4.0$  months. The mean best-corrected visual acuity at the moment of CSCR was  $0.6 \pm 0.26$  and  $0.8 \pm 0.17$  after discontinuation of corticosteroids. Neurosensory retinal detachment and pigment epithelium detachment were observed in 3 eyes, respectively. During fluorescein angiography (FA), focal dye leakage and areas of alteration of RPE were observed in 6 out of 10 eyes. Diffuse hyperfluorescence of choroidal vessels observed by ICGA was detected in all eyes. **Conclusion.** Central serous chorioretinopathy should be suspected when functional and morphological deterioration occurs in uveitis patients receiving corticosteroid therapy with no signs of inflammation reactivation. This complication is extremely rare but serious condition which needs a prompt tapering and discontinuing of corticosteroids.

**Keywords:** uveitis; treatment; central serous chorioretinopathy; corticosteroids

**Conflict of interest:** The authors declare no conflict of interest.

**Financial disclosure:** No author has a financial or property interest in any material or method mentioned.

**For citation:** Skvortsova N., Papasavvas I., Herbort Jr C.P. Central serous chorioretinopathy in uveitis patients after corticosteroid therapy: a report of 6 cases. Russian ophthalmological journal. 2021; 14 (3): 65-72 (In Russian). <https://doi.org/10.21516/2072-0076-2021-14-3-65-72>

## Центральная серозная хориоретинопатия у пациентов с увеитом после кортикостероидной терапии: шесть клинических случаев

Н.А. Скворцова<sup>1, 2</sup> ✉, И. Папасаввас<sup>2</sup>, К.П. Херборт<sup>2</sup> ✉

<sup>1</sup> Центр диагностики и хирургии заднего отдела глаза, ул. 2-я Владимирская, д. 2, стр. 2, Москва, 111123, Россия

<sup>2</sup> Центр специализированной офтальмологической помощи, отделение воспалительной и ретиальной патологии, ул. Шарль-Моннар, д. 6, 1003, Лозанна, Швейцария

**Цель работы** — описать случаи центральной серозной хориоретинопатии (ЦСХР) у пациентов с увеитом. **Материал и методы.** Представлен ретроспективный анализ, а также офтальмологические и системные особенности пациентов с увеитом, наблюдавшихся в период 20-летней работы Центра специализированной офтальмологической помощи в Лозанне (Швейцария). **Результаты.** Из 1793 пациентов с увеитом, наблюдавшихся в Центре, у 6 (0,3 %) после кортикостероидной терапии этого заболевания развилась ЦСХР. Средний возраст пациентов составлял  $40 \pm 13,4$  года, возникновение заболевания не имело связи с полом. У всех 6 пациентов выявлялись клинические признаки ЦСХР на одном глазу и субклинические на парном. Средняя продолжительность кортикостероидной терапии перед развитием ЦСХР составляла  $4,95 \pm 4,0$  месяцев. Средняя максимально скорректированная острота зрения на момент ЦСХР составляла  $0,6 \pm 0,26$  и  $0,8 \pm 0,17$  после прекращения кортикостероидной терапии. В 3 глазах наблюдалась соответственно нейросенсорная отслойка сетчатки и отслойка пигментного эпителия. В 6 глазах из 10 при флюоресцентной ангиографии выявлено фокальное просачивание красителя и зоны повреждения ретиального

пигментного эпителия. Во всех глазах отмечена диффузная гиперфлюоресценция хориоидальных сосудов, выявленная с помощью ангиографии с индоцианином зеленым. **Заключение.** При функциональном и морфологическом ухудшении у пациентов с увеитом, получающих кортикостероидную терапию, без признаков реактивации воспаления следует подозревать ЦСХР. Это крайне редкое, но серьезное осложнение, требующее незамедлительного снижения дозы и отмены кортикостероидов.

**Ключевые слова:** увеит; лечение; серозная хориоретинопатия; кортикостероиды

**Конфликт интересов:** отсутствует.

**Прозрачность финансовой деятельности:** никто из авторов не имеет финансовой заинтересованности в представленных материалах или методах.

**Для цитирования:** Скворцова Н.А., Папасаввас И., Херборт К.П. Центральная серозная хориоретинопатия у пациентов с увеитом после кортикостероидной терапии: шесть клинических случаев. Российский офтальмологический журнал. 2021; 14 (3): 65-72. <https://doi.org/10.21516/2072-0076-2021-14-3-65-72>

Central serous chorioretinopathy (CSCR) was initially described in 1866 by Albrecht von Graefe who called the disease “recurrent central retinitis” [1]. Takashi Masuda examined 192 cases and gave the name of “central serous chorioretinitis” to the disease in 1917 [2]. CSCR is one of the causes of vision loss in middle-aged predominantly male patients. The disease is characterized by the detachment of neurosensory retina (NSRD) with or without pigment epithelial detachment (PED).

Fluorescein angiography (FA) usually reveals leakage sites, demonstrating “ink-plot” or “smokestack” pattern of hyperfluorescent diffusion in acute CSCR. Multiple leakage sites, retinal pigment epithelium (RPE) atrophy, and diffuse epitheliopathy are observed in chronic cases. Indocyanine green angiography (ICGA) findings comprise increased choroidal permeability which is manifested by areas of hyperfluorescence from the mid-phase of the angiogram on and diffuse late choroidal hyperfluorescence [3]. Optical coherence tomography (OCT) signs include subretinal fluid (neurosensory retinal detachment (NSRD), PED, and disturbances of RPE in chronic cases [4].

The aetiology of CSCR remains uncertain despite the numerous studies which have been published since 1866. The recent systematic review and meta-analysis have revealed several CSCR risk factors including systemic hypertension, steroid usage, sleep disturbance, autoimmune disease, psychopharmacologic medication use, and type-A behavior [5].

One theory considers a dysfunction of the RPE ion pump as a major reason of CSCR development leading to a reverse of fluid movement from the choroid to the retina [6].

However, more recently, CSCR has been included in the newly named group of pachychoroidal diseases [7]. The pathogenesis is thought to be triggered by cortisol and aldosterone which affect the autoregulation of the choroidal vasculature. S. Kuroda, et al. reported a diffusely thickened choroid in CSCR patients [8], while Y. Chung, et al. reported an increased Haller layer both in the affected eye and the unaffected fellow eye of CSCR patients [9]. Similar changes were noted by R. Agrawal et al., who showed that the choroidal vascularity index was higher in eyes with acute CSCR in comparison to healthy eyes and resolved CSCR eyes [10]. These findings strongly suggest that both choroidal vascular dilatation and hyperpermeability play a crucial role in the development of CSCR [11]. Hyperpermeable choroidal vessels are presumed to increase hydrostatic pressure in the choroid leading to the barrier dysfunction of the RPE and fluid accumulation between the RPE and the retina [3, 11].

High endogenous serum cortisol levels [12] or corticosteroid administration in any form, systemic or topical on skin or on oral, nasal and conjunctival mucosae, are two important promoters of CSCR, as shown in numerous studies [13–19]. A relation was found between high cortisol levels in Cushing’s syndrome and thickening of the choroid and between intravitreal dexamethasone and pachychoroid and CSCR development [20, 21], indicating that

the role played by corticosteroids in the development of CSCR was through choroidal thickening.

Diagnosis of corticosteroid induced CSCR is relatively straightforward but gets a little trickier when it occurs in uveitis cases receiving systemic corticosteroid therapy.

The AIM of this study was to report a series of uveitis patients that developed CSCR.

## MATERIAL AND METHODS

Medical charts of patients treated for uveitis and presenting CSCR were retrieved for retrospective analysis. Patients had had a complete work-up applied to patients with uveitis, comprising, in addition to routine features such as Snellen visual acuity, slit-lamp examination, applanation tonometry, and funduscopy, laser flare photometry (LFP), computerized visual field (VF) testing, OCT, and dual FA and ICGA. The study was performed in accordance with the ethical standards laid down in the Declaration of Helsinki (1964) and in accordance with the IRB of our institution authorizing retrospective, anonymous and non-interventional studies.

## RESULTS

Out of 1793 uveitis patients followed at the Centre for Ophthalmic Specialised Care during a period of twenty years, 6 patients (0.3%) developed CSCR under treatment. All of them had corticosteroids in their therapeutic regimen. The mean age (range) of patients (3 men/3 women) was  $40 \pm 13.4$  (17–57) years. The mean duration of corticosteroid therapy before CSCR had occurred was  $4.95 \pm 4.0$  months. The mean best-corrected visual acuity (BCVA) at the moment of CSCR diagnosis was  $0.6 \pm 0.26$ , whereas it was  $0.8 \pm 0.17$  at last follow-up ( $p = 0.05$ , Student’s t test). Patients demographics and clinical data are presented in Table 1.

Mean LFP values were  $44.7 \pm 91.4$  ph/ms showing medium inflammation (normal value of 4–6 ph/ms). OCT which was available in 4 patients (8 eyes) revealed NSRD in 3 eyes and small PEDs in 3 eyes as well. Concomitant NSRD and PED were observed in 1 eye. In 6 out of 10 eyes, focal dye leakage and areas of alteration of RPE were observed on FA. ICGA revealed diffuse hyperfluorescence of choroidal vessels in 10 out of 10 eyes (Table 2).

Three cases are briefly reported here.

**Case 1 (patient 1 on Table 1).** A 43-year-old Caucasian man with the diagnosis of birdshot retinochoroiditis (BRC) was given oral prednisone (1 mg/kg) and cyclosporine A (5 mg/kg) 2 years after the diagnosis because of worsening of the inflammatory eye condition. The diagnosis was based on the presence of papillitis, diffuse retinal vasculitis, pseudo-delay in retinal FA arteriovenous circulation time, massive fluorescein impregnation of the retina, and cystoid macular oedema. On ICGA multifocal dark dots present in the intermediate and late ICGA phases as well as fuzziness of choroidal vessels seen during the intermediate and late phases of ICGA were typical of BRC. The HLA-A29 antigen was present. For 2 years, the patient’s condition had remained relatively

stable without treatment, BCVA remaining at 1.0 for both eyes, and laser flare photometry not detecting a subclinical anterior chamber inflammation. Both eyes had a slight vitritis and their fundus showed scattered, punched-out creamy lesions. At the moment of

corticosteroid and immunosuppressive therapy administration, the BCVA of the left eye was 0.8 with an anterior chamber inflammation having increased (laser flare photometry for OS = 15.1 ph/ms but normal values for OD (5.1 ph/ms), and visual field deterioration was noted in both eyes. After 10 weeks of systemic treatment, BCVA in both eyes was again 1.0 and LFP decreased to 5.4 ph/ms in the left eye. However, a few months later the patient presented a decrease of vision to 0.4 in the left eye with inflammatory parameters under control on both sides. FA revealed a hyperfluorescent leaking point and ICGA showed a focal brightly hyperfluorescent spot that corresponded to the leakage area on FAG (Fig. 1). All these findings were compatible with CSRC. Therefore, prednisone was progressively tapered with improvement of visual acuity to 0.7 in the left eye. It is interesting to note that hyperpermeable (hyperfluorescent) choroidal vessels were already present on ICGA before corticosteroid administration. As explained hereunder uveitis entities with predominant choroidal inflammation are more prone to secondary CSRC.

*Case 2 (patient 3 on table 1).* A 47-year-old Caucasian man presented with photophobia and vision loss in the right eye. BCVA was 0.2 for the right eye, while BCVA was 0.8 for the left. LFP revealed anterior chamber inflammation (LFP OD: 49.4 ph/ms, OS: 21.2 ph/ms). Vitritis, snowballs, retinal scars,

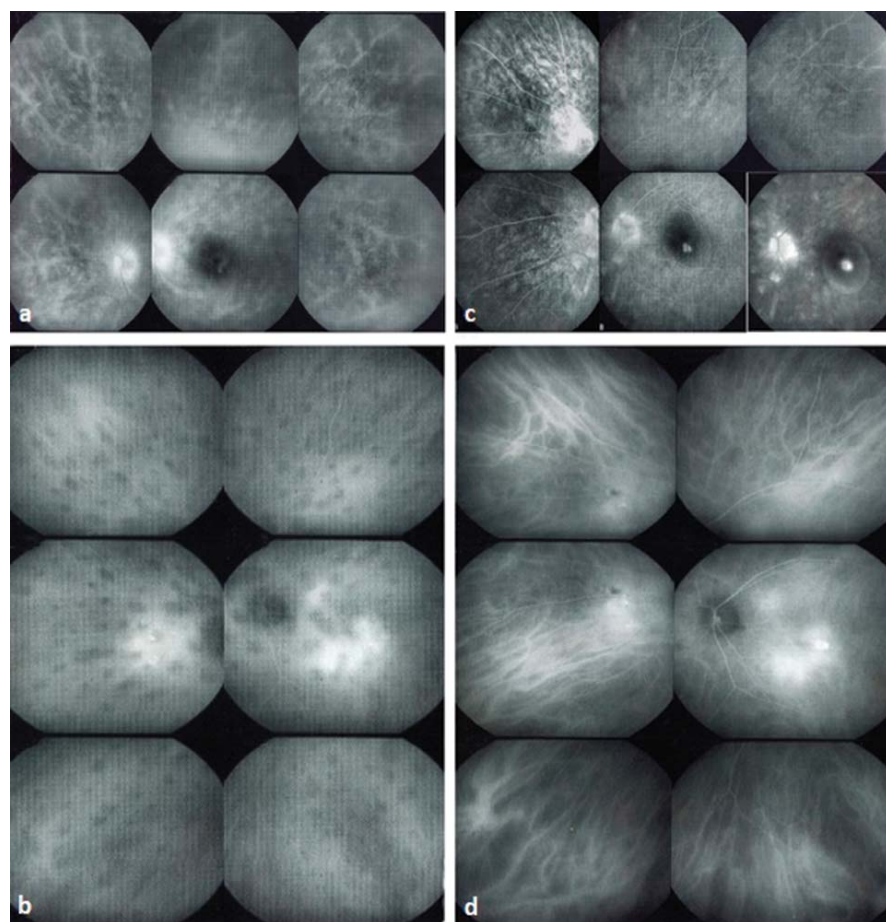
**Table 1.** Demographics and clinical data

Patient	Gender	Age	Diagnosis	Duration of corticosteroid treatment	BCVA at the moment of CSCR	BCVA at the last follow-up
1	M	43	BRC	10 weeks	0.4	0.7
2	F	35	VKH	2 months	0.9	0.7*
3	M	47	presumed TB	5 weeks	0.6	1
4	M	57	idiopathic	6 months	0.7	1
5	F	41	Scleritis, idiop.	6 months	0.2	0.6**
6	F	17	idiopathic	12 months	0.8	0.8

**Note.** BCVA — best corrected visual acuity, BRC — birdshot retinochoroiditis, VKH — Vogt — Koyanagi — Harada disease, TB — tuberculosis. \* — choroidal neovascularization successfully treated with intravitreal aflibercept injection, \*\* — after cataract surgery.

**Table 2.** Features of CSCR revealed by OCT, FAG, and ICGA

Features	Number of eyes
OCT	8 (4 patients)
Neurosensory detachment (NSRD)	3/8
Pigment Epith. Detachment (PED)	3/8
FA	10 (5 patients)
Focal dye leakage, areas of alteration of RPE	6/10
ICGA	10 (5 patients)
Hyperfluorescent leaking spot, diffuse hyperfluorescence of choroidal vessels	10/10



**Fig. 1.** Case 1. Birdshot Retinochoroiditis (left eye). (a) — FAG revealed diffuse retinal vasculitis and disc hyperfluorescence at the moment of birdshot retinochoroiditis diagnosis, (b) — ICGA revealed numerous hypofluorescent dark dots (HDDs) at the moment of birdshot retinochoroiditis diagnosis, (c) — FAG showed no signs of more active inflammation with decreased disc fluorescence, a dye leakage point, and signs of detachment of neurosensory retina at the moment of CSCR, (d) — ICGA showed decrease of HDDs, improved aspect of choroidal vessels with decreased fuzziness but hyperpermeable posterior pole choroidal vessels at the moment of CSCR [already present before corticosteroid administration (b)]

**Рис. 1.** Клинический случай 1. Ретинохориоидит Бирдшота (левый глаз). (а) — на момент постановки диагноза «ретинохориоидит Бирдшота» с помощью ФАГ выявляется диффузный ретиальный васкулит и гиперфлюоресценция диска, (б) — на момент постановки диагноза «ретинохориоидит Бирдшота» ангиография с индоцианином зеленым выявила множественные гипофлюоресцентные темные пятна (HDDs), (с) — на момент постановки диагноза ЦСХР с помощью ФАГ не выявляются признаки более активного воспаления со снижением флюоресценции диска, точек просачивания красителя и признаков отслойки нейросенсорной сетчатки, (д) — на момент ЦСХР (непосредственно перед кортикостероидной терапией) ангиография с индоцианином зеленым показала снижение HDDs, улучшение вида хориоидальных сосудов с уменьшением нечеткости, но повышенную проницаемость хориоидальных сосудов в заднем полюсе (В)



and cystoid macular oedema were observed in the right eye. Mantoux — test showed a hyper-reaction with a skin papule size of 12 × 11 mm. The diagnosis of presumed tuberculous (TB)-related uveitis was posed. After administration of triple anti-TB therapy and oral prednisone (30 mg), BCVA improved to 1.0 in both eyes in 10 days. Five weeks later, the patient presented with a decreased BCVA to 0.6 (OD), while anterior chamber inflammation had substantially decreased (LFP RE: 18.1 ph/ms, LE: 9.3 ph/ms) under 20 mg of prednisone. The condition was interpreted as a recurrence of the inflammatory process and dosage of prednisone was raised up to 50 mg. 5 days later, the patient's condition did not change but laser flare photometry decreased slightly (16.0 ph/ms on the right eye). NSRD and PED were noted. Central serous chorioretinopathy was diagnosed and steroid treatment was discontinued. 6 months later, on the last follow-up, no signs of active inflammation were seen, BCVA was 1.0 on the right eye, and LFP remained stable at 21.7 ph/ms. LFP was very helpful to precisely follow intraocular inflammation and to avoid incriminating an increase in inflammation for a decrease in function caused by CSCR (Fig. 2, 3).

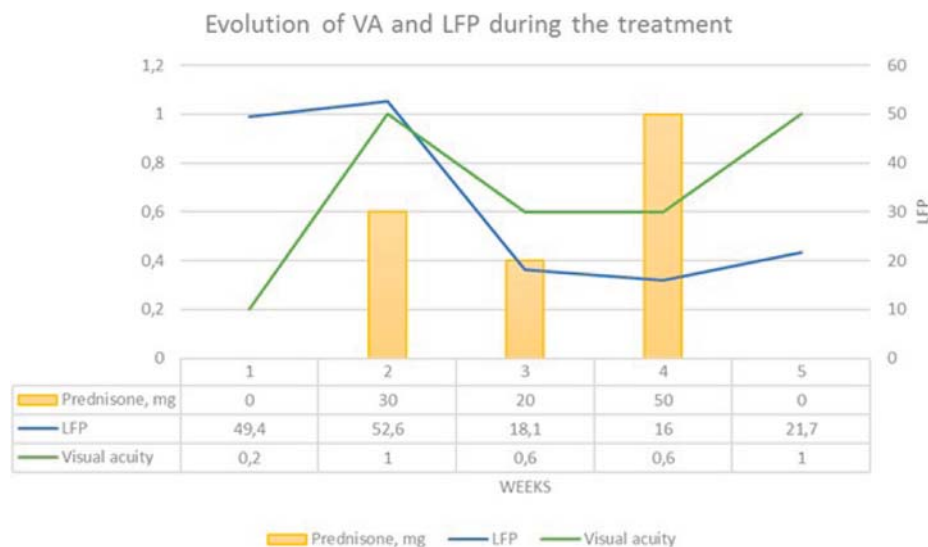
**Case 3 (patient 5 on table 1).** Inflammatory disorder had started with right-side episcleritis, myositis, scleritis, which was well controlled with local treatment in a 41-year-old Caucasian female. 4 years later scleritis had developed on the left side, and systemic corticosteroid treatment was administered. The following year, under the dose of 10 mg prednisone and methotrexate, uveitis developed on the left side. Immunosuppressive treatment was intensified (32 mg of prednisone with slow tapering plus 200 mg of azathioprine). 6 months later, the patient presented with vision deterioration in the right eye (under 24 mg of prednisone). BCVA was 0.2 for the right eye and 0.5 for the left eye, respectively. PED in the left eye (Fig. 4) was detected by FA and OCT suggestive of

CSCR. Corticosteroid therapy was stopped (following tapering during 3 months), anti-TNF-alpha therapy (Infliximab) was administered. 9 months later, the treatment regimen was azathioprine 200 mg/day, Infliximab every 6 weeks. At the last follow-up after cataract surgery, BCVA was 0.6 for the right eye and 0.5 for the left eye. LFP was 6.5 ph/ms for OD and 6.7 ph/ms for OS, respectively. OCT did not reveal NSRD nor PED in the right eye and FA did not reveal signs of papillitis nor vasculitis.

## DISCUSSION

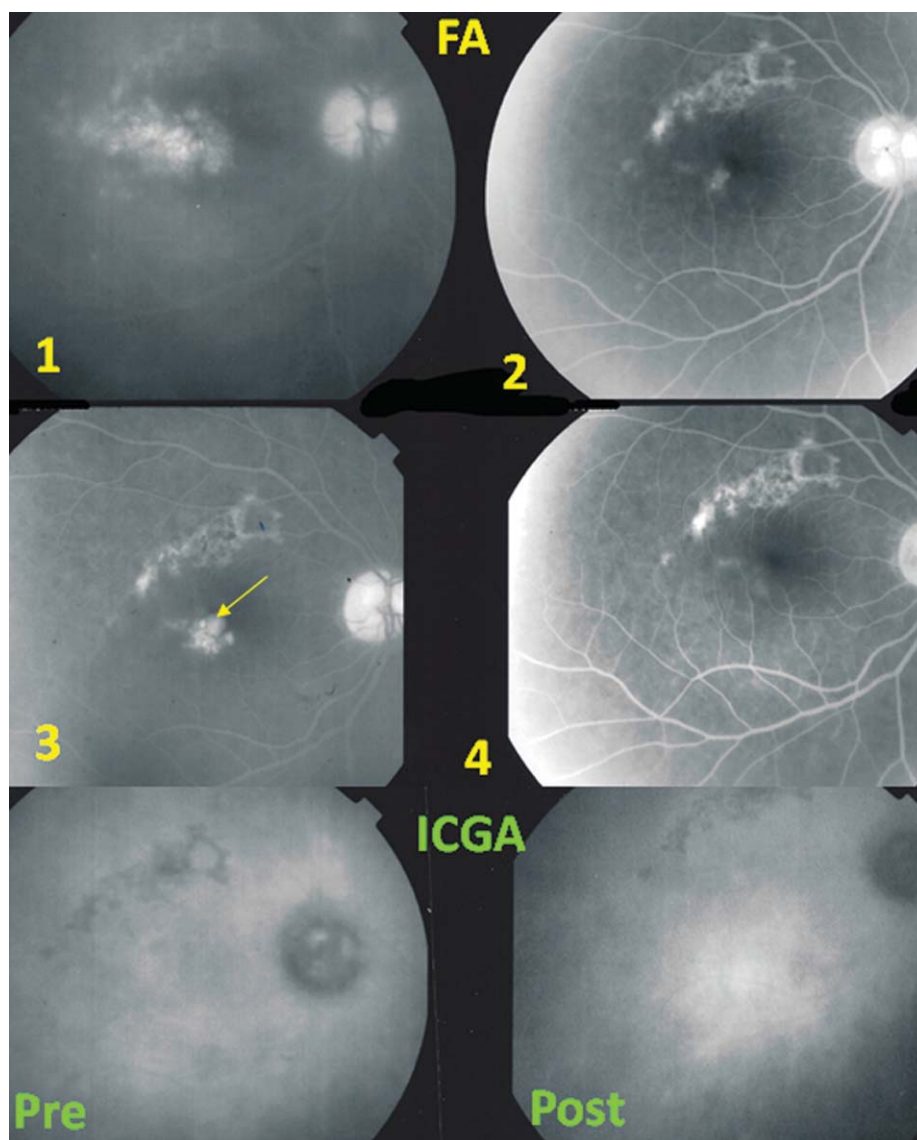
Glucocorticosteroid therapy remains the first-line treatment for the majority of ocular inflammatory diseases including uveitis. Use of systemic and local corticosteroids can be involved in CSCR development. However, reports on CSCR in posterior uveitis patients receiving corticosteroid therapy are limited [22–24, 25]. In our collective of 1793 cases of uveitis patients seen in our centre, 6 uveitis cases (0.3 %) treated with systemic corticosteroids developed CSCR. While CSCR development in autoimmune diseases has been reported often [15, 26], occurrence of CSCR in corticosteroid treated uveitis patients tends to be rare. In three of our six cases, inflammation involved the choroid. Predilection of CSCR for chorioiditis entities has been reported previously [25].

Maculopathy associated with corticosteroid use was initially reported in 1966 [27]. I. Jain and K. Singh described a case of 42-year-old male with Reiter syndrome who had been treated with oral prednisone. A serous macular detachment occurred after 1 week of treatment; therefore, Jain and Singh associated this maculopathy with corticosteroid usage. CSCR induced by corticosteroids usage has less male predisposition than the idiopathic disease. The relationship between CSCR and corticosteroids is one of the most interesting aspect of the disease. Two large retrospec-



**Fig. 2.** Case 2. Tuberculous chorioretinitis. The crucial role of LFP to distinguish between functional impact of uveitis and CSCR. Parallel evolution of visual acuity (VA) and LFP values in the right eye of the patient in relation to the dose of prednisone (mg) (orange bars). At presentation (sector 1), LFP values are high and VA is low. Following administration of 30 mg of prednisone, VA increases to 1.0 and LFP values decrease substantially (sector 2). In sector 3 VA decreases again under 20 mg of prednisone with persistent low LFP values, due to CSCR lesions. In sector 4, prednisone is erroneously increased because decrease of function was attributed to uveitis instead of CSCR. VA is again increasing, only when prednisone is discontinued (sector 5) and CSRC signs regress

**Рис. 2.** Клинический случай 2. Туберкулезный хориоретинит. Ключевая роль лазерной фотометрии (ЛФ) в дифференциальной диагностике между функциональными нарушениями при увеите и ЦСХР. Параллельные изменения остроты зрения (ОЗ) и показателей ЛФ правого глаза пациента в зависимости от дозы преднизолона (мг) (оранжевые столбцы). Вначале (колонка 1) значения ЛФ высокие, ОЗ низкая. На фоне приема 30 мг преднизолона ОЗ растет до 1,0, а показатели ЛФ значительно падают (колонка 2). В колонке 3 ОЗ снова снижена при дозе преднизолона в 20 мг и низких показателях ЛФ вследствие ЦСХР. В колонке 4 указана высокая доза преднизолона, назначенного ошибочно, поскольку снижение функций было следствием увеита, а не ЦСХР. ОЗ вновь выросла только тогда, когда прекратили терапию преднизолоном (колонка 5), признаки ЦСХР также регрессировали



**Fig. 3.** Case 2. Tuberculous chorioretinitis. FA and ICGA signs of CSCR. Top four frames show the evolution of FA signs. (1) before dual antibiotic and prednisone therapy (cystoid macular oedema and disc hyperfluorescence); (2) good response to treatment; (3) new zone of macular hyperfluorescence (arrow) due to CSCR in a quiet eye; (4) resolution of CSCR after discontinuation of corticosteroids. Bottom two frames show evolution of ICGA signs. The left frame (pre) shows the right eye before therapy. Disc hyperfluorescence on ICGA (usually non fluorescent) indicates severe posterior inflammation. Right frame (post) shows situation after treatment, in particular corticosteroids, have been stopped. Persistent ICGA hyperfluorescence explained by residual pachychoroid

**Рис. 3.** Клинический случай 2. Туберкулезный хориоретинит. Признаки ЦСХР, выявленные с помощью ФАГ и ангиографии с индоцианином зеленым. Четыре верхних снимка показывают эволюцию показателей ФАГ: (1) перед комбинированной терапией антибиотиками и преднизолоном (цистоидный макулярный отек и гиперфлуоресценция диска); (2) положительный ответ на лечение; (3) новая зона гиперфлуоресценции макулы (стрелка) из-за ЦСХР в спокойном глазу; (4) отсутствие ЦСХР после отмены кортикостероидов. Два нижних снимка демонстрируют эволюцию показателей ангиографии с индоцианином зеленым. Левый снимок — правый глаз до терапии. Гиперфлуоресценция диска на ангиографии с индоцианином зеленым (обычно нефлуоресцентной) указывает на тяжелое воспаление в заднем отделе. Правый снимок показывает ситуацию после прекращения лечения, в частности кортикостероидами. Устойчивая гиперфлуоресценция объясняется остаточным пахихороидом

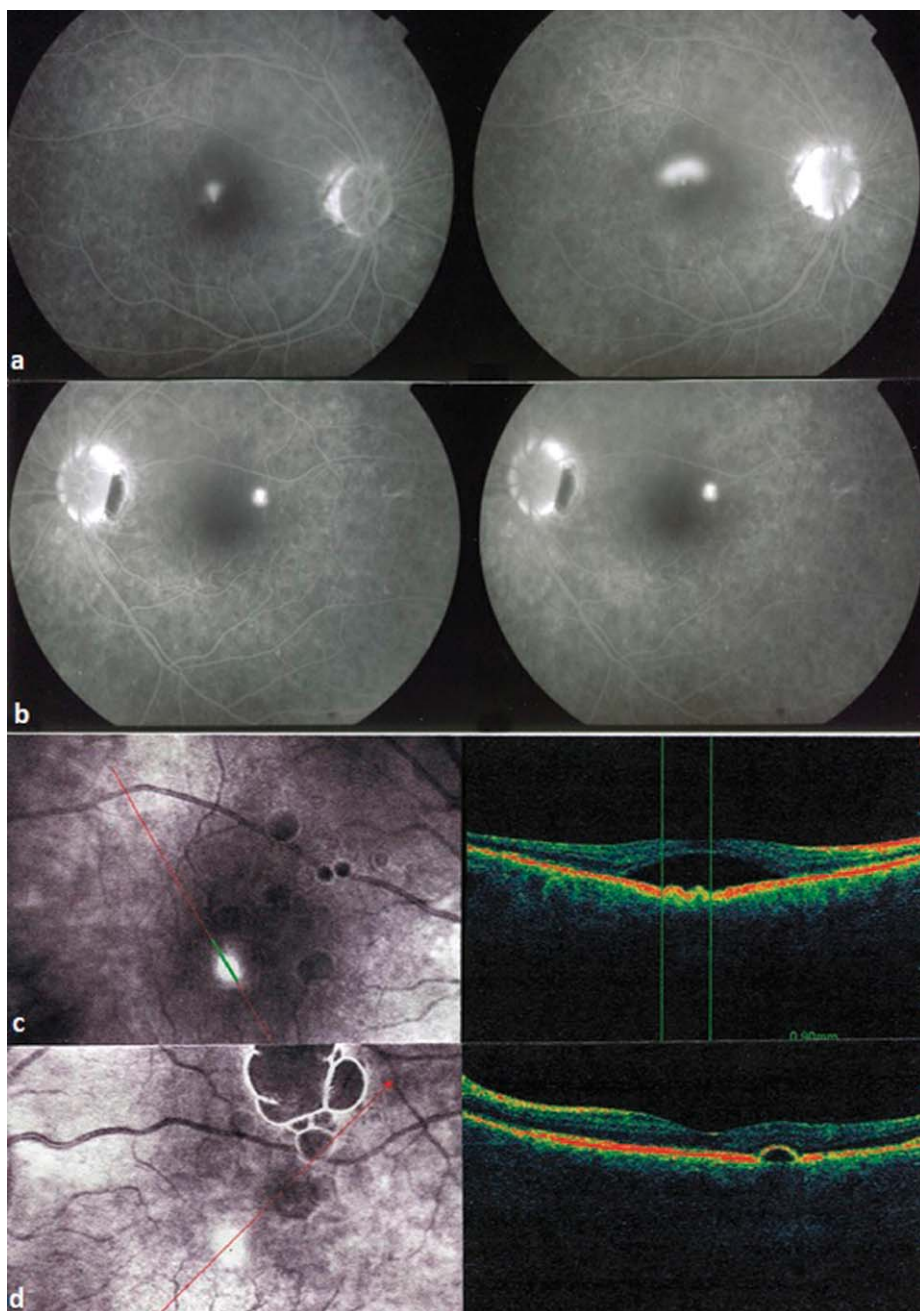
tive case-control studies with more than 200 participants were published in 1999 and 2004 and demonstrated the best evidence of association between CSCR development and corticosteroid usage [28, 29].

CSCR that develops in patients with uveitis represents a particular situation. Its diagnosis can be challenging as it may be confused with worsening of the pre-existing uveitis [24]. This is what occurred in case 2 of our series, leading to intensifying the corticosteroid treatment with exacerbation of CSCR as a consequence. Combining FA, ICGA, and OCT contributes substan-

tially to the diagnosis of CSCR during corticosteroid treatment of inflammatory eye diseases.

Laser flare photometry is another crucial investigation as it measures exactly intraocular inflammation and can so precisely exclude an inflammatory reactivation [30].

In this study, the strongest positive sign in the diagnosis of CSCR was choroidal hyperfluorescence due to hyperpermeable choroidal vessels revealed by ICGA (seen in 10 eyes out of 10, in one patient (2 eyes) ICGA was not performed). FA findings (focal dye leakage and areas of RPE alteration) and OCT findings (PED



**Fig. 4.** Case 3. Scleritis (a) FA showed a "smokestack" pattern of hyperfluorescent diffusion on the right eye (b) fa showed a point of dye leakage in the left eye, (c) — OCT revealed a detachment of neurosensory retina with RPE disturbance (small PEDs) in the right eye, (d) — OCT revealed small PED in the left eye

**Рис. 4.** Клинический случай 3. Склерит: (а) ФАГ показала картину гиперфлуоресцентной диффузии в виде «дымовой трубы» на правом глазу, (б) ФАГ выявила точку просачивания красителя в левом глазу, (с) на ОКТ видна отслойка нейросенсорной сетчатки с нарушением РПЭ (небольшие отслойки) в правом глазу, (д) на ОКТ видна небольшая отслойка пигментного эпителия в левом глазу

and NSRD) were helpful in the establishing the diagnosis of CSCR as well. Surprisingly, the simultaneous detachment of neurosensory retina and RPE was observed only in 1 eye.

There may be similarities between acute initial-onset Vogt — Koyanagi — Harada disease and bilateral CSCR. However, the ICGA and OCT patterns differ sufficiently to differentiate the diseases [31, 32].

The management of corticosteroid induced CSCR in posterior uveitis consists in diligent tapering of corticosteroid therapy and discontinuation associated with replacement by other immunosuppressive or immunomodulatory therapies [33]. If this is not sufficient, mineralocorticoid antagonists may be used as for idiopathic CSRC [34]. Indeed, glucocorticosteroid and mineralocorticoid receptors were shown to be co-expressed in the choroid and retina [35]. In our series we did not have to resort to mineralocorticoid antagonists, probably because the trigger of CSCR occurred through the glucocorticoid receptors or

through a weaker stimulation of mineralocorticoid receptors by glucocorticoids so that discontinuation of glucocorticosteroids was sufficient [36].

## CONCLUSION

Though the rate of CSCR among uveitis patients treated with corticosteroid therapy is rare, misinterpretation of CSCR as worsening of the uveitis is the pitfall to avoid. Indeed, this could lead to the vicious circle of increasing corticosteroids with its harmful consequences. Careful assessment of fundus appearance, laser-flare photometry, FA, ICGA, and OCT enable the clinician not to miss signs of CSCR. This disease should be borne in mind when vision deterioration occurs in uveitis patients under corticosteroid therapy with no signs of reactivating inflammation. It should lead the clinician to tapering and discontinuation of corticosteroids with replacement by other immunosuppressive agents, if necessary.



## References/Lumepamypa

1. Von Graefe A. Kurzere Abhandlungen. Notizen und casaistische Mittheilungen vermischten Inhalts: VI. Ueber Zentrale Recidivirende Retinitis. Albrecht Von Graefes Arch. Klein. Exp. Ophthalmol. 1866; 12: 211–5.
2. Masuda T. Central serous chorioretinitis. J. Jpn. Ophthalmol. Soc. (Nihon Ganka Gakkai Zasshi) 1917; 21: 777.
3. Spaide R.F., Hall L., Haas A., et al. Indocyanine green videoangiography of older patients with central serous chorioretinopathy. Retina. 1996; 16 (3): 203–13. doi: 10.1097/00006982-199616030-00004
4. Daruich A., Matet A., Dirani A., et al. Central serous chorioretinopathy: Recent findings and new physiopathology hypothesis. Prog. Retin. Eye Res. 2015; 48: 82–118. doi: 10.1016/j.preteyeres.2015.05.003.
5. Liu B., Deng T., Zhang J. Risk factors for central serous chorioretinopathy: a systematic review and meta-analysis. Retina. 2016; 36 (1): 9–19. doi: 10.1097/IAE.0000000000000837
6. Spitznas M. Pathogenesis of central serous retinopathy: A new working hypothesis. Graefes Arch. Clin. Exp. Ophthalmol. 1986; 224: 321–4. doi: 10.1007/BF02150023
7. Yanagi Y. Pachychoroid disease: a new perspective on exudative maculopathy. Jpn. J. Ophthalmol. 2020; 64: 323–37. doi: 10.1007/s10384-020-00740-5
8. Kuroda S., Ikuno Y., Yasuno Y., et al. Choroidal thickness in central serous chorioretinopathy. Retina. 2013; 33 (2): 302–8. doi: 10.1097/IAE.0b013e318263d11f
9. Chung Y.R., Kim J.W., Kim S.W., et al. Choroidal thickness in patients with central serous chorioretinopathy: assessment of Haller and Sattler layers. Retina. 2016; 36 (9): 1652–7. doi: 10.1097/IAE.0000000000000998
10. Agrawal R., Chhablani J., Tan K.A., et al. Choroidal vascularity index in central serous chorioretinopathy. Retina. 2016; 36 (9): 1646–51. doi: 10.1097/IAE.0000000000001040
11. Yannuzzi L.A., Slakter J.S., Gross N.E., et al. Indocyanine green angiography-guided photodynamic therapy for treatment of chronic central serous chorioretinopathy: a pilot study. Retina 2003; 23 (3): 288–98. doi: 10.1097/00006982-200306000-00002
12. Lenk J., Sandner D., Schindler L., et al. Hair cortisol concentration in patients with active central serous chorioretinopathy is elevated — a pilot study. Acta Ophthalmol. 2019; 97 (4): e568–e571. doi: 10.1111/aos.13979
13. Chaine G., Haouat M., Menard-Molcard C., et al. Central serous chorioretinopathy and systemic steroid therapy. J. Fr. Ophtalmol. 2001; 24 (2): 139–46.
14. Thinda S., Lam K., Park S.S. Unintentional secondary exogenous corticosteroid exposure and central serous chorioretinopathy. Eye (Lond). 2015; 29 (4): 577–9. doi: 10.1038/eye.2014.328
15. Ricketti P.A., Unkle D.W., Cleri D.J., et al. Central serous chorioretinopathy secondary to corticosteroids in patients with atopic disease. Allergy Asthma Proc. 2015; 36 (2): 123–9. doi: 10.2500/aap.2015.36.3827
16. Ou-Yang P.B., Qi X., Zhu X.H., et al. Central serous chorioretinopathy: signal to reduce corticoid in renal transplant recipients? Transplant Proc. 2015; 47 (7): 2236–8. doi: 10.1016/j.transproceed.2015.07.017
17. Chang Y.S., Weng S.F., Wang J.J., et al. Temporal association between topical ophthalmic corticosteroid and the risk of central serous chorioretinopathy. Int. J. Environ. Res. Public Health 2020; 17 (24): 9455. doi: 10.3390/ijerph17249455
18. Nakatsuka A.S., Khanamiri H.N., Lam Q.N., et al. Intranasal corticosteroids and central serous chorioretinopathy: a report and review of the literature. Hawaii J. Med. Public Health. 2019; 78: 151–4.
19. Ge G., Zhang Yu, Zhang Yi, et al. Corticosteroid usage and central serous chorioretinopathy: a meta-analysis. Graefes Arch. Clin. Exp. Ophthalmol. 2020; 258 (1): 71–7. doi: 10.1007/s00417-019-04486-w
20. Abalem M.F., Machado M.C., Veloso Dos Santos H.N., et al. Choroidal and retinal abnormalities by optical coherence tomography in endogenous Cushing's syndrome. Front Endocrinol (Lausanne) 2016; 7: 154. doi: 10.3389/fendo.2016.00154
21. Ersoz M.G., Hocoaglu M., Muslunas I.S., et al. Development of pachychoroid pigment epitheliopathy and transformation to central serous chorioretinopathy after intravitreal dexamethasone implantation. Retin. Cases Brief Rep. 2018; Sept 26. doi: 10.1097/ICB.0000000000000820
22. Schalenbourg A., Leys A., De Courten C., et al. Corticosteroid-induced central serous chorioretinopathy in patients with ocular inflammatory disorders. Klin. Monbl. Augenheilkd. 2002; 219 (4): 264–7. doi: 10.1055/s-2002-30660
23. Papadia M., Jeannin B., Herbolt C.P. Central serous chorioretinopathy misdiagnosed as posterior uveitis and the vicious circle of corticosteroid therapy. J. Ophthalmic Vis. Res. 2015; 10 (3): 303–8. doi: 10.4103/2008-322X.170352
24. Khairallah M., Kahloun R., Tugal-Tutkun I. Central serous chorioretinopathy, corticosteroids, and uveitis. Ocul. Immunol. Inflamm. 2012; 20 (2): 76–85. doi: 10.3109/09273948.2011.650776
25. Majumder P.D., Menia N., Sudharshan S., et al. Clinical profiles of uveitis patients developing central serous chorioretinopathy: an experience at a tertiary eye care center in India. Indian J. Ophthalmol. 2019; 67 (2): 247–51. doi: 10.4103/ijo.IJO\_831\_18
26. Pascual E.V., Martinez-Costa L., Santander F. Central serous chorioretinopathy and systemic corticosteroids in rheumatic diseases: report of three cases. BMC Musculoskelet Disord. 2015; 16: 378. doi: 10.1186/s12891-015-0843-4
27. Jain I., Singh K. Maculopathy: a corticosteroid side-effect. J. All India Ophthalmol. Soc. 1966; 14: 250–2.
28. Tittl M.K., Spaide R.F., Wong D., et al. Systemic findings associated with central serous chorioretinopathy. Am. J. Ophthalmol. 1999; 128: 63–8. doi: 10.1016/s0002-9394(99)00075-6
29. Haimovici R., Rumelt S., Melby J. Endocrine abnormalities in patients with central serous chorioretinopathy. Ophthalmology. 2003; 110 (4): 698–703. doi: 10.1016/S0161-6420(02)01975-9
30. Tugal-Tutkun I., Herbolt C.P. Laser flare photometry, a noninvasive, objective and quantitative method to measure intraocular inflammation. Int. Ophthalmol. 2010; 30 (5): 453–64. doi: 10.1007/s10792-009-9310-2
31. Shin W.B., Kim M.K., Lee C.S., et al. Comparison of the clinical manifestations between acute Vogt-Koyanagi-Harada disease and acute bilateral central serous chorioretinopathy. Korean J. Ophthalmol. 2015; 29 (6): 389–95. doi: 10.3341/kjo.2015.29.6.389
32. Lin D., Chen W., Zhang H., et al. Comparison of the optical coherence tomographic characters between acute Vogt-Koyanagi-Harada disease and acute central serous chorioretinopathy. BMC Ophthalmol. 2014; 28: 14–87. doi: 10.1186/1471-2415-14-87
33. Takayama K., Obata H., Takeuchi M. Efficacy of adalimumab for chronic Vogt-Koyanagi-Harada disease refractory to conventional corticosteroids and immunosuppressive therapy and complicated by central serous chorioretinopathy. Ocul. Immunol. Inflamm. 2020; 28(3): 509–12. doi: 10.1080/09273948.2019.1603312
34. Bousquet E., Zhao M., Daruich A., et al. Mineralocorticoid antagonists in the treatment of central serous chorioretinopathy: review of the pre-clinical and clinical evidence. Exp. Eye Res. 2019; 187:107754. doi: 10.1016/j.xer.2019.107754
35. van Dijk E.H., Nijhoff M.F., de Jong E.K., et al. Central serous chorioretinopathy in primary hyperaldosteronism. Graefes Arch. Clin. Exp. Ophthalmol. 2016; 254 (10): 2033–42. doi: 10.1007/s00417-016-3417-8
36. Daruich A., Matet A., Dirani A., et al. Central serous chorioretinopathy: recent findings and new physiopathology hypothesis. Prog. Retin. Eye Res. 2015; 48: 82–118. doi: 10.1016/j.preteyeres.2015.05.003

**Вклад авторов в работу:** К.П. Херборт — концепция и дизайн исследования, анализ литературы, написание статьи; Н.А. Скворцова, И. Папасаввас — анализ литературы, написание статьи.

**Authors' contribution:** Carl P. Herbolt Jr — is at the origin of the concept of the study, carried out the bibliographic research and the writing of the study; Natalia Skvortsova, Ioannis Papasavvas — carried out the bibliographic research and the writing of the study.

Поступила: 19.01.2021. Переработана: 14.02.2021. Принята к печати: 15.02.2021

Originally received: 19.01.2021. Final revision: 14.02.2021. Accepted: 15.02.2021

## INFORMATION ABOUT THE AUTHORS/ ИНФОРМАЦИЯ ОБ АВТОРАХ

<sup>1</sup> *Posterior Eye Segment Diagnostics and Surgery Center, 2 bld., 2, Vladimirskaia str., Moscow, 111123, Russia*

<sup>2</sup> *Inflammatory and Retinal Eye Diseases, Centre for Ophthalmic Specialised care, Rue Charles-Monnard 6, 1003 Lausanne, Switzerland*

**Natalia A. Skvortsova** — MD<sup>1, 2</sup>

**Carl P. Herbert Jr** — MD, PD<sup>2</sup>

**Ioannis Papasavvas** — FEBOphth<sup>2</sup>

**Contact information:** Natalia A. Skvortsova,  
nat.skvortsova@gmail.com

Carl P. Herbert Jr,  
cph@herbortuveitis.ch

<sup>1</sup> *Центр диагностики и хирургии заднего отдела глаза, ул. 2-я Владимирская, 2, стр. 2, Москва, 111123, Россия*

<sup>2</sup> *Центр специализированной офтальмологической помощи, отделение воспалительной и ретиальной патологии, ул. Шарль-Моннар, д. 6, Лозанна, 1003, Швейцария*

**Наталья Андреевна Скворцова** — врач-офтальмолог<sup>1, 2</sup>

**Иоаннис Папасаввас** — врач-офтальмолог<sup>2</sup>

**Карл П. Херборт мл.** — д-р медицины, профессор<sup>2</sup>

**Для контактов:** Наталья Андреевна Скворцова,

nat.skvortsova@gmail.com

Карл П. Херборт мл.

cph@herbortuveitis.ch