

# A new strategy of keratoplasty: laminating and splitting the donor cornea

O.G. Oganessian — Dr. Med. Sci., leading researcher, department of eye traumatology and reconstructive surgery

P.V. Makarov — Dr. Med. Sci., leading researcher, department of eye traumatology and reconstructive surgery

A.A. Grdikanyan — PhD student, department of eye traumatology and reconstructive surgery

V.R. Getadaryan — PhD student, department of eye traumatology and reconstructive surgery

Moscow Helmholtz Research Institute of Eye Diseases, 14/19, Sadovaya-Chernogryazskaya St., 105062, Moscow, Russia

**Purpose:** to report the first case of the same day use of a single donor cornea tissue for 5 consecutive transplantations in patients with endothelial dystrophy and keratoconus. who required anterior lamellar and endothelial keratoplasties. **Material and methods.** The Descemet membrane (DM) and the endothelium were fully detached from the stroma of the donor on the endothelial side, using first a circular and then a direct corneal cutter, forming four partial triangle-shaped Descemet grafts (each constituted a 1/4 Descemet graft). The stroma of the donor's cornea was separated by a circular cutter of a preset diameter. One patient with keratoconus underwent deep anterior lamellar keratoplasty (DALK) using the big-bubble technique. Then, each of the four Descemet grafts was sequentially transplanted by the Descemet membrane endothelial keratoplasty (DMEK) method to 4 patients with Fuchs dystrophy and pseudophakia. **Results.** During and after the surgery, there were no complications requiring additional intervention. Six months after DALK, the best corrected visual acuity (BCVA) was 0.66. Six months after four operations each using 1/4 DMEK the average BCVA was  $0.95 \pm 0.1$  (from 0.8 to 1.0) and the endothelial cell density was, respectively, 2839 after DALK and  $1680 \pm 254$  cells/mm<sup>2</sup> (from 1492 to 2039 cells/mm<sup>2</sup>) after 1/4 DMEK. **Conclusion.** One donor cornea can be successfully transplanted to at least 5 patients. Despite the fact that the implementation of DALK and several operations using the 1/4 DMEK technique within one day is technically difficult, this approach can contribute to a drastic reduction in the deficit of donor tissue and, consequently, of its cost. This approach requires a thorough selection of patients and an extensive surgical experience.

**Keywords:** donor cornea, keratoplasty, corneal transplantation, Descemet membrane transplantation, DMEK, Q-DMEK, 1/4 DMEK.

**For citation:** Oganessian O.G., Makarov P.V., Grdikanyan A.A., Getadaryan V.R. A new strategy of keratoplasty: stratification and separation of the donor's cornea. Russian Ophthalmological Journal. 2018; 11 (3): 11–18 (In Russian). doi: 10.21516/2072-0076-2018-11-3-11-18

In recent years, various anterior and posterior lamellar keratoplasty methods have become a popular operation of choice in the treatment of corneal pathologies. Because of the rapid rehabilitation, high functional results, and the noninvasive nature of the intervention, the annual increase in the number of endothelial keratoplasty with descemetorhexis — Descemet's Stripping Endothelial Keratoplasty (DSEK) and Descemet Membrane Endothelial Keratoplasty (DMEK) is observed. More and more often, these operations are performed at earlier stages of

disease development. As the life expectancy of the general population increases, so does the number of patients who need corneal transplantation. At the same time, the age of donors is increasing, and the number of intact donor corneas is decreasing due to the increasing number of surgical interventions (phacoemulsification, intraocular lenses implantation, cross-linking, implantation of intrastromal segments, rings and inlays, refractive surgery, etc.). It is clear that all of these factors will exacerbate the existing deficit of donor tissue, especially one that is intact.

According to some recent reports, about 2% of the corneas entering the tissue bank have previously undergone some refractive surgery [1].

The shortage of donor tissue is observed in many world regions. In developing countries, the annual requirement for donor tissue reaches 300,000 corneas, however, only 15,000 corneas available [2, 3].

According to the Russian Federal State Statistics Service, in 2015, 3,453 keratoplasties were performed in Russia, including 155 operations in children (citing the official website of the Federal State Statistics Service of the Russian Federation: <http://www.gks.ru/>). Evidently, in order to increase the number and availability of donor tissue, a systematic approach is required, the support of the state and society, impressive investments, time, and more. In our opinion, the most rapid and obvious way to increase the number of transplants is to use donor tissue economically, to introduce modern methods of keratoplasty, and to approach each clinical case in corneal surgery individually [4].

## MATERIAL AND METHODS

Within one day, we consecutively performed DALK on a patient with keratoconus (KC) and four operations using a ¼ DMEK technique on four patients with Fuchs dystrophy and intraocular lenses (pseudophakia). Our tasks included assessing the possibility of transplanting one donor cornea to 5 patients by consistently performing several surgical operations for one day, as well as the frequency of intraoperative complications. In the postoperative period, the number and nature of the complications, the best corrected visual acuity (BCVA), and the endothelial cell density (ECD) 6 months after the operation were recorded.

The preoperative examination of the patients included the measurement of BVCA on the optometrist projector (SZP 350, Zeiss, Germany), intraocular pressure (iCare, Finland Oy, Finland), biomicroscopy of the eye on the slit lamp (Opton 30 SL-M, Germany), assessment of the posterior segment of the eye, and kerato analysis (Galilei 6, Ziemer Ophthalmic Systems AG, Switzerland). Similar examinations, as well as measurement of ECD (Confoscan 4, Nidek Co. Ltd., Japan) were performed in all 5 cases 3 and 6 months after the operation. The minimum period of observation of all patients was 6 months.

First, the DALK operation was performed under general anesthesia. Then, ¼ DMK operations were performed under local anesthesia. The formation of all transplants and all surgical interventions were performed by a single surgeon.

All patients gave voluntary informed consent. Studies were conducted in accordance with the provisions of the Helsinki Declaration.

*Preparation of transplants.* To perform 5 operations, 1 donor cornea of a 48 years old male with the ECD of 2,774 cells / mm<sup>2</sup> was used.

The detachment of the DM with the endothelium was performed according to the previously described

procedure [5]. In brief, the technique of the operation was as follows. After aspiration fixation of the corneoscleral donor disk with the endothelium facing upwards, the DM with the peripheral tissue including the trabecular network was completely peeled off the posterior surface of the stroma (Figure 1, A). After dyeing the DM with a 0.06 % solution of trypan blue (Vision Blue, DORC International, The Netherlands), the latter was placed on a soft contact lens which was located in a donor cornea cutter (Barron vacuum donor punch; Katena Products Inc, USA) (Figure 1, B).

The Barron standard circular cutter with a diameter of 9.5 mm was used to cut out the DM from the endothelial side together with the contact lens. Without moving the DM and the contact lens, the DM and the contact lens were cut into 4 equal quarters (Figure 1, D, E, F) from the endothelial side with the help of a developed and custom-made carving machine (application for the utility model, registration No. 2017137958) (Figures 1, C, 2). All 4 parts of the DM were placed in a vial where they spontaneously folded into a roll with the endothelium facing towards the outside and floated freely in a preservative.


After marking the center and 4 major meridians, the remaining corneoscleral disc without the DM was transferred to an empty container for donor corneas and placed in a cold storage compartment.

In case of donor tissue rejection during the formation of grafts or intraoperative complications, reserve corneal tissue was available.

*Deep Anterior Lamellar Keratoplasty.* The DALK operation was performed using the big-bubble technique described by M.Anwar and K.Teichman [6]. After marking the center and the 4 main meridians of the recipient's cornea, the Hessburg — Barron Vacuum Trephine (Katena Products Inc., USA) with a 9.0 mm diameter was used to make a corneal incision as deep as 80% of the corneal stroma. After lamellar keratectomy, a disposable 30-gauge needle was used to form a 2–3 mm canal into which the DALK 27G cannula (Sarnicola, ASICO, Inc, USA) attached to a 5 ml syringe was introduced. The cannula was guided to the center of the cornea as close as possible to the DM, and, by pressing the plunger of the syringe, the cornea was pneumatized to form a big-bubble with a diameter smaller than the diameter of the keratectomy.

Without removing the cannula, the paracentesis was performed and the anterior chamber of the eye was partially emptied. After this, the air was introduced into the cornea until the diameter of the big-bubble was equal to the diameter of the keratectomy (Figure 3, A). The big-bubble was opened with a blade, and a cohesive viscoelastic (Healon GV, AMO, USA) was introduced into its cavity. The residual part of the stroma was removed with blunt microsurgical scissors by cutting the stroma crosswise and lengthwise. Afterwards, the surface of the DM was thoroughly washed from the viscoelastic (Figure 3, B).

A corneoscleral donor disk without DM was placed in a Barron die cutter to cut a 9.0 mm diameter graft,




**Fig. 1.** Images of surgical steps of Q-grafts preparation. A — the detached DM with the adjacent trabecular meshwork from the donor's corneoscleral button. B — the isolated DM with the adjacent trabecular meshwork was placed onto a contact lens located on the Barron vacuum donor punch. C — the DM and the underlying contact lens were first divided into 2 equal halves with a custom made single used punch for linear cutting of the DM (view from above) with a semicircular blade (black arrows). D — after a 90-degree turn of the cutting block, each half of DM was then again divided into 2 equal halves with the same custom-made punch. E — after a double cut 4 pieces of contact lens and F — 4 pieces of Q-grafts of DM for Q-DMEK were obtained.

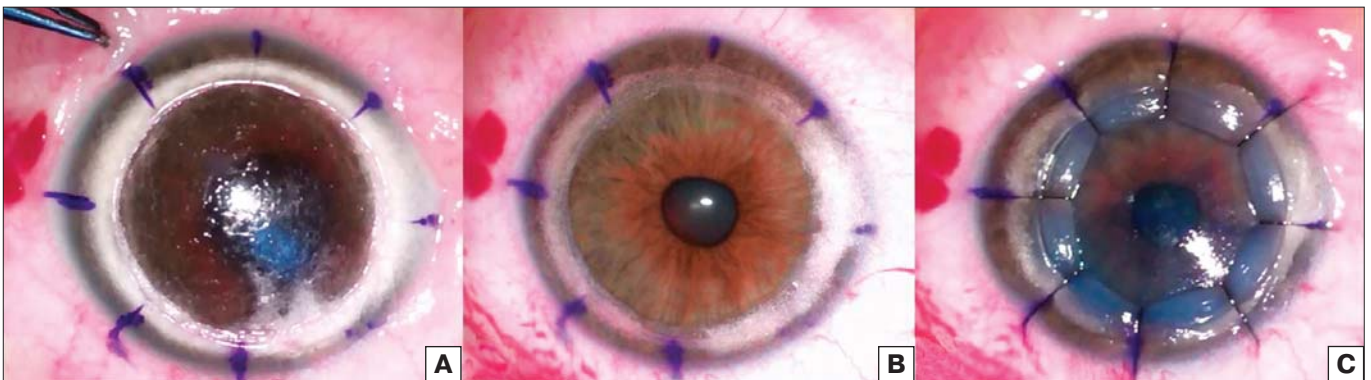which was then fixed in the cornea of the recipient with 8 nodal (Figure 3, C) and one continuous nylon seam 10/0.

In the postoperative period, medical therapy included eye drops of 0.1 % dexamethasone every 4 hours, eye drops of 0.5 % moxifloxacin hydrochloride 3 times a day, and tear substitutes without preservatives every 4 hours. Antibiotic therapy was discontinued 3 weeks after the operation, and the frequency of instillation of other drugs gradually decreased within 6 months.

*Partial transplantation of descemet membrane with endothelium (¼DMEK).* The ¼ DMEK technique was identical in all 4 cases, and, generally, it was similar to the standard DMEK technique described earlier [7].



**Fig. 2.** Custom-made punch for linear cutting of the DM. A — a longitudinal view of the punch with a semicircular blade (black arrows). B — a transverse view of the punch with a semicircular blade (black arrows).



**Fig. 3.** Images of surgical steps during DALK. A — formation of the big-bubble equal to the trephination diameter. B — the stroma was removed and the host's DM was denuded. C — the donor button was sutured in place using 8 interrupted 10-0 monofilament nylon sutures.



After implementing a single paracentesis in the 10 hour meridian, the descemetorexis (7.0–8.0 mm) was performed under air with the help of a reverse Sinsky hook (DORC International, the Netherlands). The lumbar tunnel incision with a width of 1.6 mm was performed in the 12 hour meridian with the help of keratome (MANI inc., Japan). Partial Descemet grafts were stained with 0.06 % trypan blue solution and aspirated by a 18G catheter (Apexmed International BV, Netherlands) attached to a 2 ml syringe and filled with BSS solution ("Descemet Membrane Transplantation Method — microinvasive descemetoplasty", RF patent No. 2394532 from 20.07.2010). The graft was inserted into the anterior chamber of the recipient's eye by irrigation through a formed incision in the 12 hour meridian. By *ab externo*, the graft was centered, the roll was opened with the endothelium facing downwards, and the front chamber was completely filled with air, which was left for at least 2 hours. Two hours after the operation, a part of the air was released through a paracentesis under a biomicroscope.

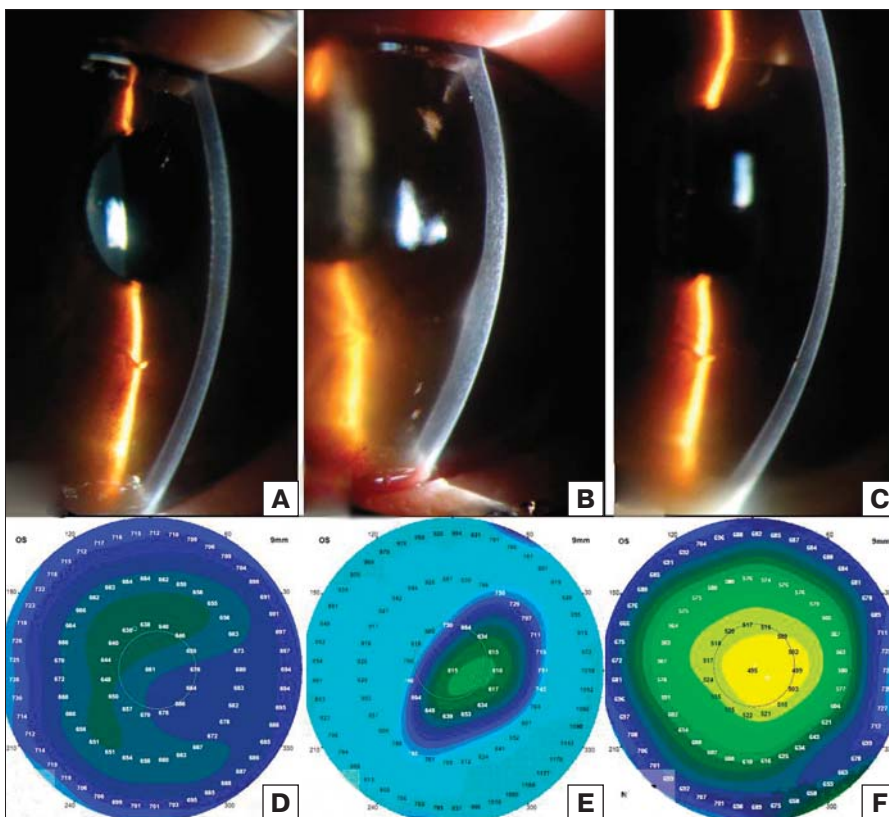
During and after the surgery, there was no development of any complications requiring interventions. After the operation, in all cases, 0.1 % dexamethasone eye drops were administered every 4 hours, 0.5 % moxifloxacin hydrochloride eye drops were administered 3 times a day, and tears replacements without preservatives were administered every 4 hours. Antibiotic therapy was discontinued 2 weeks after the operation, and the frequency of

instilling the remaining medications was gradually reduced within 6 months.

## RESULTS

The age of the patient who underwent DALK surgery was 52 years. The BCVA before the operation was 0.16, and 6 months after the operation it improved to 0.66. During the last examination, the patient did not experience any complications, and the transplant retained its transparency. Confocal microscopy showed ECD equal to 2,839 cells/mm<sup>2</sup>. The mean age of patients undergoing Q-DMEK operations was 69 ± 1.1 years (range 52 to 70 years). The average BCVA before the operation was 0.35 ± 0.1, and 6 months after ¼ DMEK, it increased to 0.95 ± 0.1. During the last examination, all corneas retained their transparency. 6 months after the operation, the average ECD decreased from 2,774 cells/mm<sup>2</sup> to 1,680 ± 254 cells/mm<sup>2</sup> (from 1,492 to 2,039 cells/mm<sup>2</sup>).

Partial non-adhesion of Descemet grafts took place in 2 out of 4 cases of ¼ DMEK. Nevertheless, in no case was it necessary to re-introduce air into the anterior chamber. Examination was performed under a slit biomicroscope 6 months after surgery. After the operation, all partial Descemet grafts were completely adherent. Other complications, such as graft rejection, endothelial incompetence, or Urrets-Zavalía syndrome were not recorded for the whole observation period (Figures 4, 5).

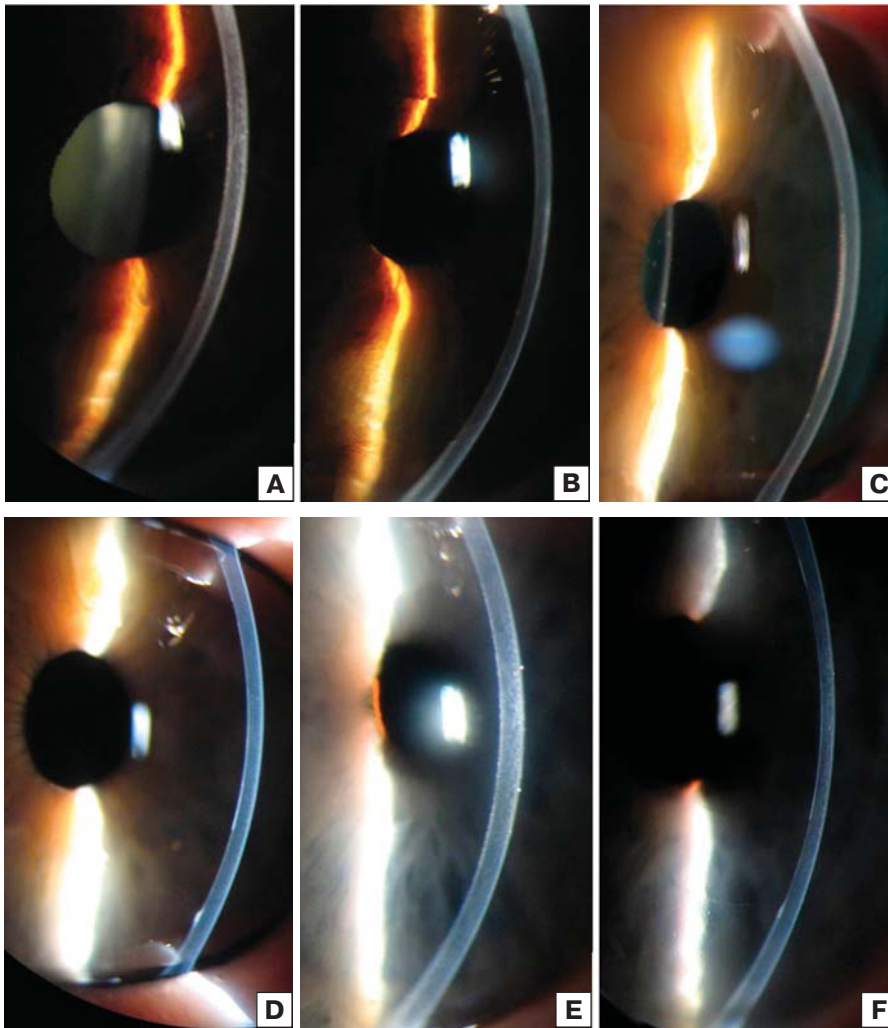


**Fig. 4.** Q-DMEK case # 1. Slit-lamp images and pachymetry maps before the operation (A, D), 3 days (B, E), and 6 months (C, F) after Q-DMEK. Pachymetry maps, as well as slit-lamp images, show gradual cornea thinning.

## DISCUSSION

The first successful corneal transplant was carried out by Eduard Zirm in 1905. He was also the first to apply the principle of rational use of donor tissue by performing 2 partially penetrating keratoplasties from 1 donor cornea [8]. There are several publications on the use of 1 donor cornea for several transplants. R. Vajpayee et al. described the use of 1 corneoscleral donor disk to treat 3 patients who underwent anterior stratified keratoplasty, endothelial keratoplasty (DSEK), and limbal stem cell transplantation [4]. J. Lie et al. developed a technique for simultaneously executing 2 operations from 1 donor cornea [9]. There are other publications on the conserved use of donor tissue, suggesting that a significant deficit of donor corneas in many parts of the world is a significantly big problem [10–15]. Stratification and separation of donor tissue can be one way to reduce the deficit of donor tissue.

Separation of donor tissue into parts is actively used in other areas of



**Fig. 5.** Q-DMEK cases #2 (A, B), #3 (C, D) and #4 (E, F). Slit-lamp images before the operation (A, C, E) and at 6 months (B, D, F) after Q-DMEK. Slit-lamp images show absence of any detachment of Q-graft and the decreased corneal thickness after surgery.

clinical transplantology. For example, dividing the liver reduces the need for donor livers by about 40% [16, 17]. The annual need for donor corneas in developing countries is approximately 300,000, while only 15,000 grafts are available, and almost half of them are not suitable for transplantation [4]. We believe that the criteria for assessing the suitability of donor tissue for transplantation should be revised because today it is possible to successfully transplant both the donor cornea as a whole and individual layers that were previously discarded [1, 18–25]. The use of lamellar keratoplasty in urgent surgery can be a manifestation of the rational use of donor tissues [26–30].

The presented clinical cases demonstrate the possibility of consecutively carrying out 5 operations — DALK and 4  $\frac{1}{4}$  DMEK in one day, using 1 donor cornea. Examination performed 6 months after transplantation showed that a partial DMEK allowed to achieve the same indicators of BCVA and ECD as the standard DMEK operation. The strategy of using 1 donor cornea for several transplants, which was first implemented by

E. Zirm, opens the possibility of a significant increase in the number of transplants performed by the available volumes of donor corneas. Theoretically, it is still possible to increase the number (up to 6) of transplantations performed, provided that donor limbal tissue is used for allo-limbal transplantation.

In this study, we described the first case of obtaining five transplants from a single donor cornea. The  $\frac{1}{4}$  DMEK method combines the advantages of a standard DMEK and the implantation of a descemet membrane with the endothelium (DMET). The main advantage of DMEK in comparison to other methods is the rapid restoration of vision. The main advantage of  $\frac{1}{4}$  DMEK, as compared to conventional DMEK and  $\frac{1}{4}$  DMEK, is the maximum effective use of the donor cornea. In addition,  $\frac{1}{4}$  DMEK allows for saving more recipient cells and at the same time creates favorable conditions for endothelialization, since descemetorexis at  $\frac{1}{4}$  DMEK is always larger than the size of the partial descemetograft. Doing  $\frac{1}{4}$  DMEK is completely justified, since the pathological changes in Fuchs's dystrophy mainly affect a limited area, usually located in the center of the cornea. To carry out  $\frac{1}{4}$  DMEK, a strict selection of patients is needed based on the potential of visual acuity, the

depth of the anterior chamber, and the area and degree of endothelial dystrophy. The mean BCVA of all patients with Fuchs' dystrophy and artifacts before  $\frac{1}{4}$  DMEK was  $0.35 \pm 0.1$  (0.2 to 0.4), indicating that there were initial and minor changes in the structure of the cornea.

Conducting a one-day operation of DALK and subsequent operations  $\frac{1}{4}$  DMEK requires complex logistics — the simultaneous presence of all patients in the clinic, prompt and adequate preoperative patient training, timely postoperative examination, backup donor material, and professionalism of the surgical team. Nevertheless, despite the complexity of such a strategy, its advantages are obvious. Conserved use of donor tissue is one of the most important, obvious, and affordable ways to rapidly increase the number of transplants and, consequently, cured patients. Such an approach to application of laminating and splitting the donor cornea can significantly reduce the deficit of donor tissues. We believe that the preliminary preparation and filling of partial Descemet grafts into eye banks can greatly facilitate the  $\frac{1}{4}$  DMEK technique.



## CONCLUSION

Presented clinical cases show that one donor cornea can be successfully transplanted to at least 5 patients. Although the consistent implementation of DALK and four ¼ DMEK during one operational day represents technical and logistical difficulties, the presented strategy contributes to a drastic reduction in the deficit of corneal tissue. It is important to note that this strategy requires a strict selection of patients for ¼ DMEK.

**Conflict of interests:** there is no conflict of interests.

**Financial disclosure:** No author has a financial or property interest in any material or method mentioned.

## References

1. Phillips P., Terry M., Shamie N., et al. Descemet's stripping automated endothelial keratoplasty (DSAEK) using corneal donor tissue not acceptable for use in penetrating keratoplasty as a result of anterior stromal scars, pterygia, and previous corneal refractive surgical procedures. *Cornea*. 2009; 28: 871–6. doi: 10.1097/ICO.0b013e318199f8d7
2. Tandon R., Verma K., Vanathi M., et al. Factors affecting eye donation from postmortem cases in a tertiary care hospital. *Cornea*. 2004; 23: 597–601.
3. Krishnaiah S., Kovai V., Nutheti R., et al. Awareness of eye donation in the rural population of India. *Indian J. Ophthalmol.* 2004; 52: 73–8.
4. Vajpayee R.B., Sharma N., Jhanji V., et al. One donor cornea for 3 recipients: a new concept for corneal transplantation surgery. *Arch. Ophthalmol.* 2007; 125: 552–4. doi: 10.1001/archoph.125.4.552
5. Groeneveld-van Beek E.A., Lie J.T., von der Wees J., et al. Standardized 'no-touch' donor tissue preparation for DALK and DMEK: harvesting undamaged anterior and posterior transplants from the same donor cornea. *Acta Ophthalmol.* 2013; 91: 145–50. doi: 10.1111/j.1755-3768.2012.02462.x
6. Anwar M., Teichmann K.D. Deep lamellar keratoplasty: surgical techniques for anterior lamellar keratoplasty with and without baring of Descemet's membrane. *Cornea*. 2002; 21: 374–83.
7. Oganessian O.G., Neroev V.V., Gundorova R.A., Vorobjeva M.A. The first experience of descemet's membrane transplantation. *Oftal'mologija*. 2008. 5: 18–22 (in Russian).
8. Zirm E. Eine erfolgreiche totale keratoplastik. *Arch. Ophthalmol.* 1906; 64: 580–93.
9. Lie J.T., Groeneveld-van Beek E.A., Ham L., et al. More efficient use of donor corneal tissue with Descemet membrane endothelial keratoplasty (DMEK): two lamellar keratoplasty procedures with one donor cornea. *Br. J. Ophthalmol.* 2010; 94: 1265–6. doi: 10.1136/bjo.2009.171629
10. Heindl L.M., Riss S., Bachmann B.O., et al. Split cornea transplantation for 2 recipients: a new strategy to reduce corneal tissue cost and shortage. *Ophthalmology*. 2011; 118: 294–301. doi: 10.1016/j.ophtha.2010.05.025
11. Sharma N., Agarwal P., Titiyal J., et al. Optimal use of donor corneal tissue: one cornea for two recipients. *Cornea*. 2011; 30: 1140–4. doi: 10.1097/ICO.0b013e318209d23c
12. Müller T.M., Lavy I., Baydoun L., et al. Case report of Quarter-Descemet membrane endothelial keratoplasty for Fuchs endothelial dystrophy. *Cornea*. 2017; 36: 104–7. doi: 10.1097/ICO.0000000000001008
13. Yoeruek E., Schmidt K.U. Current approaches to combat the shortage of corneal tissues: split-DMEK and double-split keratoplasty. *Cornea*. 2015; 34: 6–9. doi: 10.1097/ICO.0000000000000341
14. Rasouli M., Caraiscos V.B., Slomovic A.R. Efficacy of routine notification and request on reducing corneal transplantation wait times in Canada. *Can. J. Ophthalmol.* 2009; 44: 31–5. doi: 10.3129/i08-187
15. De By T.M. Shortage in the face of plenty: improving the allocation of corneas for transplantation. *Dev. Ophthalmol.* 2003; 36: 56–61.
16. Otte J.B., de Ville de Goyet J., Alberti D., et al. The concept and technique of the split liver in clinical transplantation. *Surgery*. 1990; 107: 605–12.
17. Cintorino D., Spada M., Gruttadauria S., et al. In situ split liver transplantation for adult and pediatric recipients: an answer to organ shortage. *Transplant Proc.* 2006; 38: 1096–8. doi:10.1016/j.transproceed.2006.02.146
18. Armour R., Ousley P., Wall J., et al. Endothelial keratoplasty using donor tissue not suitable for full-thickness penetrating keratoplasty. *Cornea*. 2007; 26: 515–9. doi:10.1097/ICO.0b013e3180335511
19. Moshirfar M., Khalifa Y., Davis D., et al. Descemet stripping automated endothelial keratoplasty using donor corneas with previous laser in situ keratomileusis or photorefractive keratectomy: a case series and donor cap histopathology. *Cornea*. 2012; 31: 533–7. doi: 10.1097/ICO.0b013e31820142be
20. Maharana P., Jhanji V., Vajpayee R.B. Inadvertent use of cornea with previous LASIK in deep lamellar keratoplasty. *Optom. Vis. Sci.* 2014; 91: 59–62. doi: 10.1097/OPX.0000000000000162
21. Huang T., Wang Y., Hu A., et al. Use of pediatric donor tissue in Descemet's stripping endothelial keratoplasty. *Br. J. Ophthalmol.* 2009; 93: 1625–8. doi: 10.1136/bjo.2009.158477
22. Kim P., Yeung S.N., Lichtinger A., et al. Descemet stripping automated endothelial keratoplasty using infant donor tissue. *Cornea*. 2012; 31: 52–4. doi: 10.1097/ICO.0b013e31821eeac0
23. Sun Y.X., Hao Y.S., Hong J. Descemet membrane stripping endothelial keratoplasty with neonate donors in two cases. *Br. J. Ophthalmol.* 2009; 93: 1692–9. <http://dx.doi.org/10.1136/bjo.2009.158188>
24. Oganessian O.G., Yakovleva S.S., Kharlampidi M.P., et al. The rationale application of donor material: original 251 ten years' experience, possible ways of development and literature data. *Meditsinskij zhurnal Rossijskoj Federatsii*. 2016; 22: 193–7 (in Russian).
25. Neroev V.V., Oganessian O.G., Gundorova R.A., et al. Use of keratotomy eyes as a transplant. *Rossijskij meditsinskij zhurnal*. 2011; 5: 32–4 (in Russian).
26. Fang W., Xiuming J., Yesheng X., et al. Treatment of corneal perforation with lenticules from small incision lenticule extraction surgery: a preliminary study of 6 patients. *Cornea*. 2015; 34: 658–63. doi: 10.1097/ICO.0000000000000397
27. Graue-Hernandez E.O., Zuniga-Gonzalez I., Hernandez-Camarena J.C., et al. Tectonic DSAEK for the management of impending corneal perforation. *Case Reports in Ophthalmol. Med.* 2012; Article ID 916528, 4 pages. <http://dx.doi.org/10.1155/2012/916528>
28. Nahum Y., Bahar I., Busin M. Tectonic Descemet stripping automated endothelial keratoplasty for the management of sterile corneal perforations in decompensated corneas. *Cornea*. 2016; 35: 1516–9. doi: 10.1097/ICO.0000000000001037
29. Tu E.Y. Descemet membrane endothelial keratoplasty patch for persistent corneal hydrops. *Cornea*. 2017; 36: 1559–61. doi: 10.1097/ICO.0000000000001351
30. Kolomeyer A.M., Chu D.S. Descemet stripping endothelial keratoplasty in a patient with keratoglobus and chronic hydrops secondary to a spontaneous Descemet membrane tear. *Case Reports in Ophthalmol. Med.* 2013; ID 697403. doi: 10.1155/2013/697403.

Received: 19.12.2017

**For contacts:** Oganessian Oganess  
E-mail: oftalmolog@mail.ru